University J Dent Scie 2026; Vol. 12, Issue 3

Conservative Multidisciplinary Management of a Severely Compromised Maxillary Lateral Incisor with Advanced Periodontal Bone Loss: A Six-Month Case Report

Abstract:
Advanced periodontal bone loss in anterior teeth presents a therapeutic challenge, with extraction often considered. Conservative multidisciplinary treatment may permit preservation of selected teeth. This report describes a 24-year-old male with a severely compromised maxillary lateral incisor diagnosed with localized Stage III Grade B periodontitis. Clinical examination revealed Grade I mobility and a 15-mm probing depth, while radiographic evaluation showed vertical bone loss extending to the apical third. Following Phase I periodontal therapy and previously completed root canal treatment, intracoronal splinting, open flap debridement, and regenerative grafting with NovaBone® Putty were performed. At six months, probing depth decreased to 3 mm, pathological mobility resolved, and approximately 50–60% radiographic defect fill extended to the middle root third. The tooth was preserved.

Key-words: Periodontitis; Intrabony defect; NovaBone® Putty; Periodontal regeneration; Tooth preservation; Multidisciplinary management.

Introduction:

Periodontitis is a chronic inflammatory disease associated with dysbiotic dental biofilm, resulting in progressive destruction of the periodontal ligament, cementum, and alveolar bone. Advanced disease may cause attachment loss, tooth mobility, and eventual tooth loss [1]. Management of severe periodontal defects, particularly in the esthetic anterior region, remains challenging because treatment should control disease while preserving function, esthetics, and the natural dentition [2]. Although extraction followed by implant-supported rehabilitation may be considered for severely compromised teeth, a multidisciplinary approach combining endodontic, periodontal, and restorative procedures can improve the prognosis of selected teeth [3,4].

Regenerative periodontal therapy is widely used for managing intrabony defects. Alloplastic graft materials are biocompatible, readily available, and avoid donor-site morbidity [5]. Bioactive glass possesses osteoconductive and osteostimulatory properties that support bone formation and defect healing [6]. NovaBone® Putty, a premixed bioactive calcium phosphosilicate graft, provides favorable handling, defect adaptation, and graft stability [7]. This report describes the multidisciplinary management of a severely compromised maxillary lateral incisor using endodontic treatment, intracoronal splinting, open flap debridement, and regenerative grafting, with favorable six-month clinical and radiographic outcomes.

Case Presentation:

A 24-year-old systemically healthy male presented to the Department of Periodontology with mobility of tooth 12 for

[1]SOFIYA SITHARTHAN, [2]SRINIVASAN SIVAPRAGASAM, [3]RAJASEKAR SUNDARAM, [4]KAVITHA JAYAVEL,
[1-4]Department of Periodontology,
Government Dental College and Hospital, Cuddalore District, Chidambaram, Tamil Nadu

Address for Correspondence: Dr. Sofiya Sitharthan Post Graduate,
Department of Periodontics, Government Dental College and Hospital, No 91/6, Meenakumariillam, Vallalar Street, Near Sherwood school, Muthaiahnagar, Chidambaram-608002, Cuddalore
E-mail: svsofiyashan1998@gmail.com

Received : 8 Aug., 2026 **Published :** 30 Sep., 2026

Access this article online

Website:
www.ujds.in

DOI:
.....

How to cite this article: .....UNIVERSITY JOURNAL OF DENTAL SCIENCES, 12(1).

six months. His medical and family histories were noncontributory.

Clinical examination revealed Grade I mobility, a probing pocket depth of 15 mm, erythematous and edematous gingiva and bleeding on probing in the affected region(Figure1).



Figure 1. Preoperative clinical photograph demonstrating localized periodontal inflammation, bleeding on probing, and deep periodontal pocketing in relation to the maxillary right lateral incisor (tooth 12).

An intraoral periapical radiograph (IOPA) demonstrated severe vertical bone loss extending to the apical third of the root, widening of the periodontal ligament space, and loss of the lamina dura in relation to tooth 12 (Figure 2). Based on the clinical and radiographic findings, localized Stage III Grade B periodontitis was diagnosed. Root canal treatment of the affected tooth had been completed previously.

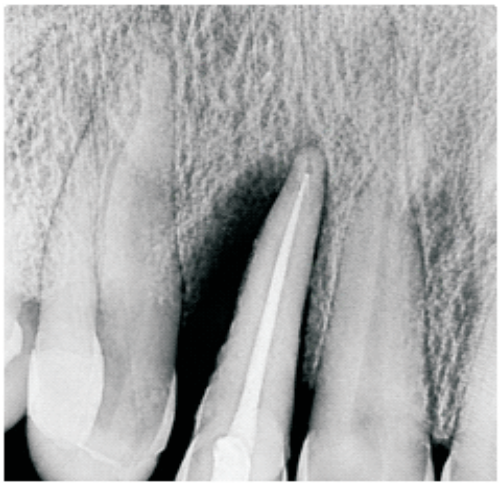

Figure 2. Preoperative IOPA showing severe vertical bone loss extending to the apical third of tooth 12, with widening of the periodontal ligament space and loss of the lamina dura.

Following a comprehensive periodontal examination, Phase I therapy comprising oral hygiene instructions and full-mouth scaling and root planing was performed. The patient was subsequently re-evaluated before definitive periodontal treatment. Considering his young age and the possibility of preserving the natural tooth, a conservative multidisciplinary approach was selected. Treatment, expected benefits, possible risks, alternative option of extraction, and need for regular maintenance were explained to the patient. Written informed consent was obtained before initiating the surgical procedure and for publication of clinical records. Intracoronal splinting extending from teeth 13 to 23 was performed to stabilize tooth 12 (Figure 3).



Figure 3. Intracoronal splinting extending from tooth 13 to tooth 23 for stabilization of the mobile tooth 12.

Under local infiltration anesthesia, regenerative periodontal surgery was performed in relation to teeth 11, 12, and 13. An internal bevel incision followed by sulcular and interdental incision was made. A vertical releasing incision was placed distal to tooth 13, and a triangular full-thickness mucoperiosteal flap was elevated to the mucogingival junction (Figure 4).



Figure 4. Intraoperative view demonstrating the reflected mucoperiosteal flap and thorough debridement of the intrabony defect associated with tooth 12.

Thorough debridement and root surface decontamination with 24% EDTA were performed. The intrabony defect was grafted with NovaBone® Putty, which was carefully adapted to the osseous defect (Figures 5 and 6). The flap was repositioned to obtain primary closure and secured with simple interrupted sutures (Figure 7).



Figure 5. Intraoperative view showing delivery of **NovaBone® Putty** into the intrabony periodontal defect of tooth 12 using a dispenser gun to achieve complete adaptation within the osseous defect.



Figure 6. Intraoperative view showing NovaBone® Putty dispensed from the cartridge and completely adapted to the intrabony periodontal defect.



Figure 7. Final intraoperative view showing flap repositioning and stabilization with simple interrupted sutures following regenerative periodontal therapy with **NovaBone® Putty**.

Postoperatively, amoxicillin 500 mg and metronidazole 400 mg were prescribed three times daily for five days. Ibuprofen 400 mg was advised as required for pain, and 0.2% chlorhexidine mouthwash was prescribed twice daily for two weeks. Oral hygiene instructions were reinforced, and periodic follow-up visits were scheduled.

At three months, the patient was asymptomatic and showed satisfactory soft-tissue healing. The probing pocket depth had decreased from 15 mm to 5 mm, while radiographic examination demonstrated early defect fill (Figure 8). At six months, the periodontal tissues appeared healthy, without inflammation or bleeding on probing. Tooth 12 was clinically stable, and the probing pocket depth had decreased to 3 mm. Radiographic evaluation demonstrated approximately 50–60% defect fill extending to the middle third of the root, indicating favorable healing and successful preservation of the tooth (Figure 9).



Figure 8. Three-month postoperative IOPA demonstrating favorable radiographic healing with evidence of early bone formation in relation to tooth 12.



Figure 9. Six-month postoperative IOPA demonstrating substantial radiographic bone fill within the intrabony defect, extending to the middle third of the root irt tooth 12.

Discussion:

Management of advanced periodontal bone loss is challenging, particularly in young adults, for whom preserving the natural dentition is preferable whenever feasible. Multidisciplinary treatment combining endodontic therapy, splinting, periodontal surgery, and regenerative grafting may improve the prognosis of compromised teeth. In this case, treatment reduced probing depth and produced approximately 50–60% radiographic defect fill at six months.

Bioactive glass grafts possess osteoconductive and osteostimulatory properties that support defect healing. *Koduru et al.* reported probing-depth reduction, clinical attachment gain, and radiographic bone fill with NovaBone® Putty. Its handling characteristics facilitated adaptation and stability within intrabony defects [8]. Similarly, the material was adapted within the defect and was associated with favorable healing.

Grover et al. reported a mean probing-depth reduction of 4.21 mm, clinical attachment gain of 2.71 mm, and 64.76% radiographic bone fill at six months. Reduced tooth mobility was also observed following regenerative treatment [9]. These findings are comparable to this case, in which probing depth decreased from 15 mm to 3 mm, pathological mobility resolved, and substantial radiographic defect fill occurred.

Naqvi et al., Hazari et al., and Lakshmi Narayanan et al. also reported improvements in probing depth, clinical attachment level, and radiographic defect resolution using NovaBone Putty, alone or combined with platelet-rich fibrin [7], [10]. Favorable healing in the present case was achieved without an additional biological modifier.

This case is notable because a lateral incisor with bone loss extending to the apical third was retained through conservative multidisciplinary management. Nevertheless, radiographic defect fill does not confirm histological periodontal regeneration. The short follow-up and single-case design limit generalization. Longer observation is required to assess the stability of the clinical and radiographic outcomes.

Conclusion:

A multidisciplinary approach involving endodontic therapy, intracoronal splinting, open flap debridement, and NovaBone Putty preserved a compromised maxillary lateral incisor. At six months, probing depth and pathological mobility decreased, with substantial radiographic defect fill. Careful case selection and maintenance are essential when considering conservative treatment before extraction in young patients.

References:

1. Könönen E, Gursoy M, Gursoy UK. Periodontitis: A Multifaceted Disease of Tooth-Supporting Tissues. J Clin Med. 2019;8(8):1135.
2. Mankoo T, Frost L. Rehabilitation of esthetics in advanced periodontal cases using orthodontics for vertical hard and soft tissue regeneration prior to implants - a report of 2 challenging cases treated with an interdisciplinary approach. Eur J Esthet Dent. 2011;6(4):376-404
3. Bădărău-șuster AM, Bechir ES, Bardocz-Veres Z, et al. Recent Advances in Regenerative Therapies in Periodontology. Dent J (Basel). 2025;13(12):564.
4. Solanki S, Gandhi N, Mohanty R, Kokila G, Baig MN, Issrani R. A Multidisciplinary (Endo-Prostho-Perio) Management of Infected Teeth-Hope for the Hopeless. J Pharm Bioallied Sci. 2025;17(Suppl 2):S1520-S1522.
5. Sharma S, Tomar N, Ahmed S, Kaushik M. Healing Patterns of Periodontal Intrabony Defects Following Allograft and Alloplast Therapy: A Prospective Randomized Clinical Trial. Cureus. 2026;18(2):e103311.
6. Motta C, Cavagnetto D, Amoroso F, Baldi I, Mussano F. Bioactive glass for periodontal regeneration: a systematic review. BMC Oral Health. 2023;23(1):264.
7. Hazari V, Choudhary A, Mishra R, Chandrashekar KT, `Trivedi A, Pathak PK. Clinical and Radiographic Analysis of Novabone Putty with Platelet-Rich Fibrin in the Treatment of Periodontal Intrabony Defects: A Randomized Control Trial. Contemp Clin Dent. 2021;12(2):150-156.
8. Koduru S, Aghanashini S, Nadiger S, Apoorva SM, Bhat D, Puvvalla B. A Clinical and RadiographicEvaluation of the Efficacy of Nanohydroxyapatite (Sybograf™) versus Bioactive Calcium Phosphosilicate Putty (Novabone®) in the Treatment of Human Periodontal Infrabony Defects: A Randomized Clinical Trial. Contemp Clin Dent. 2019;10(1):16-23.
9. Grover V, Kapoor A, Malhotra R, Uppal RS. Evaluation of the efficacy of a bioactive synthetic graft material in the treatment of intrabony periodontal defects. J Indian Soc Periodontol. 2013;17(1):104-110.
10. Naqvi A, Gopalakrishnan D, Bhasin MT, Sharma N, Haider K, Martande S. Comparative Evaluation of Bioactive Glass Putty and Platelet Rich Fibrin in the Treatment of Human Periodontal Intrabony Defects: A Randomized Control Trial. J Clin Diagn Res. 2017;11(7):ZC09-ZC13.