

# Analysis Of Dermatoglyphics and Cheiloscopy Patterns in Hypertensive and Type II Diabetes Mellitus Patients - A Clinical Study

## Abstract:

Development of hypertension is strongly impacted by hereditary and environmental variables. Diabetes mellitus (DM) is a systemic disease that is mostly defined by genetics and is closely linked to family medical history. Positive medical history increases the probability of disease risk. Hence the investigation of correlation of dermatoglyphics patterns as well as cheiloscopy patterns helps in early diagnosis of hypertension as well as type II diabetes mellitus.

**Aim** - to investigate the incidence of dermatoglyphics and cheiloscopy patterns in hypertensive and type II diabetes mellitus patients within the North Indian population.

**Materials and Method** : In this study 500 patients were enrolled ( aged  $\geq 40$  years), Group 1 :- 150 patients having history of hypertension, group 2 :- 150 patients having history of type II DM, group 3 patients :- 200 patients having history of both hypertension and type II diabetes mellitus. Lipprint patterns were captured with red flamed lip color and cello tape where as fingerprint patterns were captured with the help of stamp ink pad on white bond paper.

**Results**: Cheiloscopy analysis showed the prevalence of branched and reticular type of patterns in hypertension and type II diabetes mellitus patients. No gender statistically significant difference was seen with respect to cheiloscopy patterns in hypertension as well as in type II diabetes mellitus patients. Dermatoglyphic patterns showed the predominance of whorl and ulnar loop pattern in all the three groups. Gender statistical significant difference was observed.

**Conclusion**: The study concludes that the occurrence of type II diabetes mellitus and hypertension may be determined using dermatoglyphic and cheiloscopy patterns, respectively.

**Key-words**: Dermatoglyphic, cheiloscopy, type II diabetes mellitus, hypertension.

## Introduction:

The term dermatoglyphics has been derived from the greek word that is "derma" means skin and "glyph" which means carving. This term was coined by Professor **Harlod Cummins** and **Mildo** in 1943. This science of dermatoglyphic goes deep into the analysis of dermal patterns on the foot digits, hand digits, soles and palms. In terms of functionality, these ridges improve touch sensitivity while providing a solid grip to avoid slipping. Additionally referred to as "Dactylography," "Dactyloscopy," or the "**Henry-Galton**" categorization scheme, fingerprint pattern analysis is used to identify individuals. The following categories have also been applied to the dermatoglyphic print patterns [1].

### Access this article online

**Website:**  
www.ujds.in

**DOI:**  
<https://doi.org/10.21276/ujds.2026.12.1.3>

<sup>1</sup>DAMINI, <sup>2</sup>BHAWANDEEP KAUR,  
<sup>3</sup>GAURAV GOYAL, <sup>4</sup>PUNEET RUSTOGI,  
<sup>5</sup>CHANCHALGEET KAUR, <sup>6</sup>RAJNI AGNIHOTRI  
<sup>1,3</sup>Department of Oral Medicine & Radiology, Genesis institute of Dental Sciences & Research, Ferozpur.  
<sup>2,4,5,6</sup>Department of Oral Medicine & Radiology, Genesis institute of Dental Sciences & Research, Ferozpur.

**Address for Correspondence:** Dr. Damini,  
Post Graduate student, Department of Oral Medicine & Radiology, Genesis institute of Dental Sciences & Research, Ferozpur.  
Email: mdamini511@gmail.com

**Received** : 26 April, 2025, **Published** : 31 March, 2026

**How to cite this article:** Damini, Bhawandeep kaur, Gaurav Goyal, Puneet Rustogi, Chanchalgeet Kaur, & Rajni Agnihotri. (2026). Analysis of Dermatoglyphics and Cheiloscopy Patterns in Hypertensive and type II Diabetes Mellitus Patients - A Clinical Study. UNIVERSITY JOURNAL OF DENTAL SCIENCES, 12(1).

### Arch pattern:

The most basic kind of dermatoglyphic pattern is this one. 1 or more than 1 ridge that enters from one end, create a central elevation, and exit from another end and combine to form it. There are two more types.

- (a) **Plain pattern:** This pattern has a small upward slope in the middle.
- (b) **Tented pattern:** The central height in this pattern resembles a tent.

### Loop pattern:

A delta and a core make up this fingerprint pattern. It recurs at the center after entering and leaving from one side to the other. Additionally, it is classified into 2 categories:

- (a) **Radial pattern:** This dermatoglyphic pattern terminates towards the thumb after recurring.
- (b) **Ulnar pattern:** In this, the dermatoglyphic pattern recurs, exiting in the direction of smallest digit.

### Whorl pattern:

Two deltas and a core make up this fingerprint pattern type. It may be classified further into sub categories.

- (a) **Plain-whorl pattern:** A loop encircling a central core is organized in concentric circles to make this pattern.
- (b) **Central pocket-looped whorl pattern:** A little loop made up of two delta loops forms this kind of fingerprint pattern.
- (c) **Double-loop whorl pattern:** There are two whorls and two double loops in this kind of finger print pattern.
- (d) **Composite whorls:** Two deltas surround a centre core in this finger print pattern.

'Sulci labiorum' is another term for lip prints. 'Cheiloscopy' is the term used to describe the examination of grooves on lips. The fields of dermatoglyphic and cheiloscopic pattern examination are strongly associated with the study of evolution, biology, medicine, genetics, and forensic sciences. Greek words "cheilos," which means lips, and "skopein," which means "to see," are the origin of the word "cheiloscopy" [2].

Cheiloscopy is defined as a technique which is mainly used for the purpose of personnel identification with respect to specific lip furrows. **Edmond locard** and **Le Moyne Snyder**

have emphasized the significance of lip impression patterns in relation to their stability, permanence, and resistance to climate change.

According to the **Suzuki** and **Tsuchihashi** lips prints can be categorized into the following classifications [3].

- (a) Type I :- complete vertical grooves running across vermillion zone of lip
- (b) Type ii :- branched grooves
- (c) Type iii :- reticular groove
- (d) Type iv :- intersected grooves
- (e) Type v :- no morphological differentiation of grooves

Genes causing different dermatoglyphic patterns significantly increase the risk of familial illnesses, diabetes mellitus being the most common. Moreover, dermatoglyphic pattern anomalies have been observed in situations involving genetic aberrations [4].

Numerous investigations were conducted to identify the most common lipprint pattern in various states and racial groups. Lip prints were matched with thumb and finger prints, skeletal measurements, and blood group to ascertain the individual's gender. Studies were conducted to employ cheiloscopy as a genetic marker in patients with diabetes, hypertension, and cancer [5].

In light of this, the current study was carried out to look into the prevalence of Dermatoglyphs and Cheiloscopy patterns in type II DM and HTN patients in North India.

### Materials and Method:

The study was performed on 500 subjects aged  $\geq 40$  years with a history of HTN and type II DM for more than 5 years, who reported to the daily Outpatient Department (OPD) of Oral Medicine and Radiology at Genesis Institute of Dental Sciences and Research, Ferozepur, Punjab. All subjects were briefed about the study's aim & objectives, and written informed consent was obtained. Institutional ethical approval was obtained to conduct the study.

### Material and Methodology: For Cheiloscopic patterns

Red flamed lip stick (lakme red glossy lipstick), lip brush, cellophane tape (45mm width), metallic scale, black marker, scissor, cotton, A4 JK bond paper, magnifying glass (10 cm diameter).

**For Dermatoglyphic patterns:**

Blue stamp pad of Faber- Castell company (110x 69mm), white A4 JK bond paper, magnifying glass (10 cm diameter).

**Inclusion criteria:**

- (1) Hypertensive subjects with blood pressure (equal to or more than 140/100 mmHg) of  $\geq 5$  years duration.
- (2) Subjects with type II diabetes with fasting blood glucose levels (equal to or more than 100 mg/dl) of  $> 5$  years duration.

**Exclusion criteria:**

- (1) Subjects having age less than 40 years
- (2) Juvenile diabetic patients
- (3) Pregnant females having hypertension
- (4) Subjects having hormonal imbalance
- (5) Subjects having any allergy history specially, contact dermatitis.
- (6) Subjects with any other systemic illness.
- (7) Subjects having any other deformity over the fingers of right hand.

**Method:**

The lips were cleansed using a cotton swab. A red lip stick was evenly applied along the vermilion borders in a single stroke using a lip brush. Subjects were instructed to rub their lips together to ensure uniform distribution of the lipstick. After 2-3 minutes, cellophane tape with adhesive was placed over the lipstick. Lip prints were then obtained in the natural resting position by pressing first in the center and then along the corners of the lips.

The cellophane strip is subsequently affixed onto the white bond paper for archival purposes, following which the lip prints were scrutinized using the "Tsuchihashi" classification system. Each lip print was segmented into six regions, commencing from the upper right area to the lower right area (designated as A1 to A6). The lip print type was evaluated in all six regions, and the prevailing type was determined by identifying the most frequently occurring pattern.

For the fingerprints, the dominant hand of the subjects was utilized, as 85% of individuals are right-handed, aligning with the preference of most government agencies for this side. The impressions of all five fingers were captured on identical A4-size white bond paper. Each individual's gathered fingerprints were encoded. The fingerprint patterns were scrutinized according to Henry's classification methodology, employing a magnifying glass for analysis.



Figure 1: Armamentarium for lip prints (A) Gloves (B) Mouth mask (C) Kidney tray, cotton; (D) Cleansing milk (E) Red lipstick (F) Cellophane tape (G) Scissor (H) Bond paper

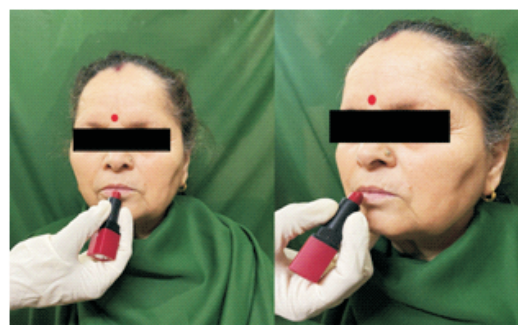

Figure 2 : Procedure of recording lip prints



Figure 3 : Division of lipprints from right upper to right lower area

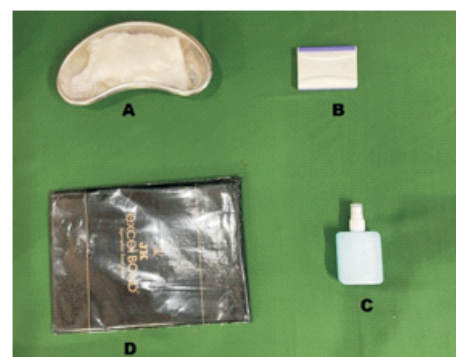

Figure 4 : Armamentarium for finger prints (A) Kidney tray, cotton; (B) Blue stamp pad ;(C) Cleansing milk; (D) Bond paper




Figure 5 : Finger print patterns evaluated

**Results:**

The present study was conducted in the department of Oral Medicine and Radiology of Genesis institute of dental sciences and research with the aim of investigating the incidence of cheiloscopy and dermatoglyphic patterns in hypertension as well as in type II diabetes mellitus patients. 500 subjects were taken and after randomization, three study groups were formed as follows:

- Group 1 : Hypertension patients (n=150)
- Group 2 : Diabetes mellitus patients (n=150)
- Group 3 : Patients suffering from both hypertension as well as diabetes mellitus (n=200)

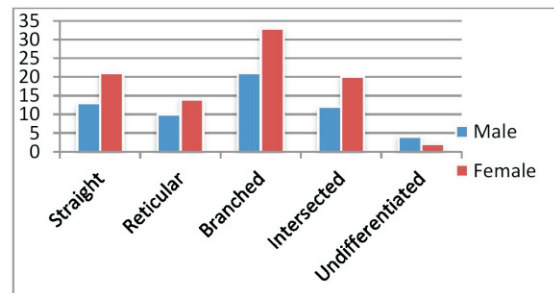
**Table 1**

Group 1 patients were classified according to the gender and cheiloscopy patterns were analyzed in group 1 patients. In males branched pattern (35%) was seen predominantly followed by straight pattern (21.6%), intersected pattern (20%), reticular pattern(16.6%) and undifferentiated pattern (6.66%). In females branched pattern(36.6%) was seen predominantly followed by straight pattern (23.3%), intersected pattern (22.2%), reticular pattern(15.5%) and undifferentiated pattern (2.22%). Chi square value with respect to gender was 1.961 and p value was insignificant that is 0.743.

Table no 1

Cheiloscopy patterns	Males	Females	Total	Mean	Standard deviation
Straight	13 (21.6%)	21 (23.3%)	34 (22.60%)	0.62	0.493
Reticular	10 (16.6%)	14 (15.5%)	24 (16%)	0.58	0.504
Branched	21 (35%)	33 (36.6%)	54 (36%)	0.61	0.492
Intersected	12 (20%)	20 (22.22%)	32 (21.3%)	0.63	0.492
Undifferentiated	4 (6.66%)	2 (2.22%)	6 (4%)	0.33	0.516
Total	60	90	150	0.60	0.492

	Gender wise
Chi square value	1.961
P value	0.743



Graph 1: Distribution of Cheiloscopy Patterns in Hypertensive Patients

**Table 2**

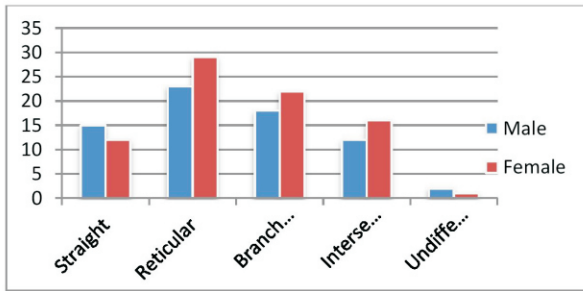
Group 2 patients were classified according to the gender and cheiloscopy patterns were analyzed in group 2 patients. In males reticular pattern (32.8%) was seen predominantly followed by branched pattern (25.7%), straight pattern (21.4%), intersected pattern(17.1%) and undifferentiated pattern (2.8%). In females reticular pattern(36.25%) was seen predominantly followed by branched pattern (27.5%), intersected pattern (20%), straight pattern(15%) and undifferentiated pattern (1.2%). Chi square value with respect to gender was 2.984 and p value was insignificant that is 0.561.

Distribution of Cheiloscopy Patterns in Type II Diabetes Mellitus Patients

Table No 2

Cheiloscopy patterns	Males	Females	Total	Mean	Standard deviation
Straight	15 (21.4%)	12 (15%)	27 (18%)	0.41	0.501
Reticular	23 (32.8%)	29 (36.25%)	52 (34.6%)	0.56	0.502
Branched	18 (25.7%)	22 (27.5%)	40 (26.6%)	0.55	0.504
Intersected	12 (17.1%)	16 (20%)	28 (18.6%)	0.61	0.497
Undifferentiated	2 (2.8%)	1 (1.2%)	3 (2%)	0.33	0.577
Total	70	80	150	0.53	0.501

Chi square value	Gender wise
	2.984
P value	0.561



Graph 2: Distribution of Cheiloscopic Patterns in Type II Diabetes Mellitus Patients

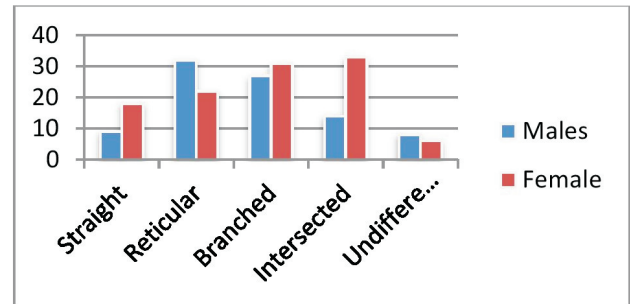
**Table 3**

Group 3 patients were classified according to the gender and cheiloscopic patterns were analyzed in group 3 patients. In males reticular pattern (35.5%) was seen predominantly followed by branched pattern (30%), intersected pattern (15.5%), straight pattern (10%) and undifferentiated pattern (8.8%). In females intersected pattern (30%) was seen predominantly followed by branched pattern (28.1%), reticular pattern (20%), straight pattern (16.3%) and undifferentiated pattern (5.4%). Chi square value with respect to gender was 11.206 and p value was significant that is 0.024. Distribution of Cheiloscopic patterns in Hypertensive and Type II Diabetes Mellitus Patients

Table No 3

Cheiloscopic patterns	Males	Females	Total	Mean	Standard deviation
Straight	9 (10%)	18 (16.3%)	27 (13.5%)	0.59	0.503
Reticular	32 (35.5%)	22 (20%)	54 (27%)	0.55	0.501
Branched	27 (30%)	31 (28.1%)	58 (29%)	0.53	0.503
Intersected	14 (15.5%)	33 (30%)	47 (23.5%)	0.60	0.497
Undifferentiated	8 (8.8%)	6 (5.4%)	14 (7%)	0.43	0.514
Total	90	110	200	0.55	0.499

Chi square value	Gender wise
	11.206
P value	0.024*



Graph 3: Distribution of Cheiloscopic patterns in Hypertensive and Type II Diabetes Mellitus Patients

**Table 4**

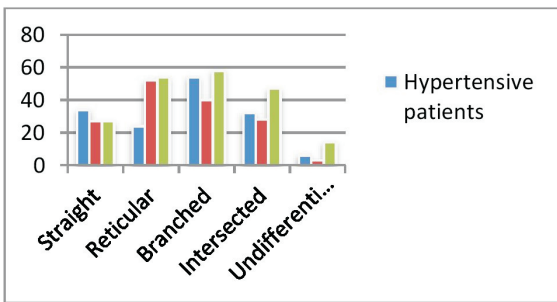
Cheiloscopic patterns analysis was compared in group 1, 2 and 3 patients. Branched type of pattern (36%) was predominantly seen in group 1 patients followed by straight pattern (22.60%), intersected pattern (21.3%), reticular pattern (16%) and undifferentiated pattern (4%). Chi square test value for group 1 was 13.746 and p value was 0.008 that is significant. In group 2 patients reticular type of pattern (34.6%) was predominantly seen followed by branched pattern (26.6%), intersected pattern (18.6%), straight pattern (18%) and undifferentiated pattern (2%). Chi square test value was 11.34 for group 2 patients and p value was significant that is 0.026. In group 3 patients branched type of pattern (29%) was predominantly seen followed by reticular pattern (27%), intersected pattern (23.5%), straight pattern (13.5%) and undifferentiated pattern (7%). Chi square test value was 8.38 for group 3 patients and p value was insignificant that is 0.078.

Comparison of Cheiloscopic Patterns in Hypertensive patients, Type II Diabetes Mellitus Patients and Patients with both Hypertension and Type II Diabetes Mellitus

Table No 4

Cheiloscopic patterns	Hypertensive Patients	Type II Diabetes Mellitus Patients	Patients with both Hypertension and Type II Diabetes Mellitus.	Total
Straight	34(22.60%)	27(18%)	27(13.5%)	88(17.6%)
Reticular	24(16%)	52(34.6%)	54(27%)	130(26%)
Branched	54(36%)	40(26.6%)	58(29%)	152(30.4%)
Intersected	32(21.3%)	28(18.6%)	47(23.5%)	107(21.4%)
undifferentiated	6(4%)	3(2%)	14(7%)	23(4.6%)
Total	150	150	200	500

Chi-square value	Hypertensive patients	Type II diabetes mellitus patients	patients with both hypertension and type ii diabetes mellitus.
	13.746	11.34	8.38
P value	0.008*	0.026*	0.078*



Graph 4 : Comparison of Cheiloscopy Patterns in Hypertensive patients, Type II Diabetes Mellitus Patients and Patients with both Hypertension and Type II Diabetes Mellitus

**Table 5**

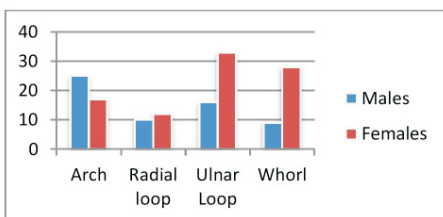
Group 1 patients were classified according to the gender and dermatoglyphic patterns were analyzed in group 1 patients. In males ulnar loop pattern(38.3%) was seen predominantly followed by arch pattern (31.6%) ,radial loop pattern (16%), and whorl pattern (13.3%).In females ulnar loop pattern(35.5%) was seen predominantly followed by whorl pattern (32.2%) ,arch pattern (18.8%) and radial loop pattern(13.3%).Chi square value with respect to gender was 11.834 and p value was significant that is 0.008.

Distribution of Dermatoglyphic Patterns in Hypertensive Patients

Table No 5

Ridge pattern	Males	Females	Total	Mean	Standard deviation
Arch pattern	25(31.6%)	17(18.8%)	42(24%)	0.47	0.506
Radial loop pattern	10(16%)	12(13.3%)	22(14.6%)	0.55	0.510
Ulnar loop pattern	16(38.3%)	33(35.5%)	49(36.6%)	0.58	0.498
Whorl pattern	9(13.3%)	28(32.2%)	37(24.6%)	0.78	0.417
Total	60	90	150	0.60	0.492

Gender wise	
Chi square value	11.834
P value	0.008*



Graph 5 : Distribution of Dermatoglyphic Patterns in Hypertensive Patients

**Table 6**

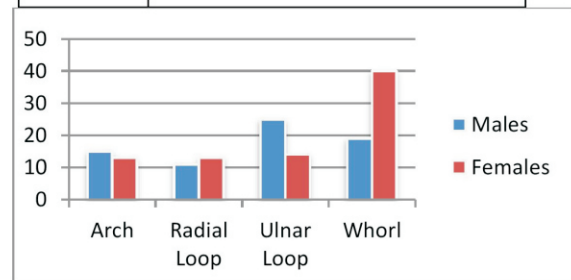
Group 2 patients were classified according to the gender and dermatoglyphic patterns were analyzed in group 2 patients. In males ulnar loop pattern(35.7%) was seen predominantly followed by whorl pattern (27.14%) ,arch pattern (21.4%), and radial loop pattern(15.7%).In females whorl pattern(50%) was seen predominantly followed by ulnar loop pattern (17.5%) ,arch pattern and radial loop pattern were equally seen (16.25%).Chi square value with respect to gender was 10.266 and p value was significant that is 0.016.

Distribution of Dermatoglyphic Patterns in type II Diabetes Mellitus Patients

Table No 6

Ridge pattern	Males	Females	Total	Mean	Standard deviation
Arch pattern	15(21.4%)	13(16.25%)	28(18.6%)	0.46	0.505
Radial loop pattern	11(15.7%)	13(16.25%)	24(16%)	0.60	0.503
Ulnar loop pattern	25(35.7%)	14(17.5%)	39(26%)	0.57	0.502
Whorl pattern	19(27.14%)	40(50%)	59(39.3%)	0.53	0.503
Total	70	80	150	0.53	0.501

Gender wise	
Chi square value	10.266
P value	0.016*



Graph 6 : Distribution of Dermatoglyphic Patterns in type II Diabetes Mellitus Patients

**Table 7**

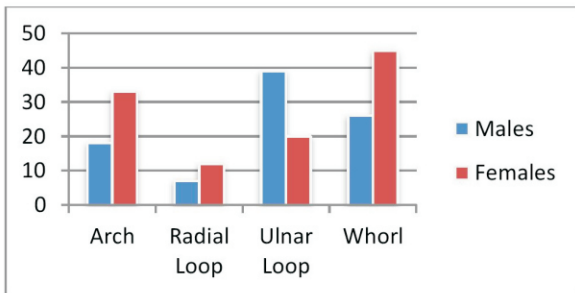
Group 3 patients were classified according to the gender and dermatoglyphic patterns were analyzed in group 3 patients. In males ulnar loop pattern(43.3%) was seen predominantly followed by whorl pattern (28.8%), arch pattern (20%), and radial loop pattern(7.7%).In females ulnar loop pattern(50%) was seen predominantly followed by arch pattern (24.5%) ,whorl pattern(18.1%) and radial loop pattern were equally seen (7.2%).Chi square value with respect to gender was 15.082 and p value was significant that is 0.002.

Distribution of Dermatoglyphic Patterns in Hypertensive Patients and Type II Diabetes Mellitus Patients

Table No 7

Ridge pattern	Males	Females	Total	Mean	Standard deviation
Arch pattern	18(20%)	33(24.5%)	51(22.5%)	0.60	0.495
Radial loop pattern	7(7.7%)	12(7.2%)	19(7.5%)	0.53	0.516
Ulnar loop pattern	39(43.3%)	20(50%)	59(47%)	0.59	0.495
Whorl pattern	26(28.8%)	45(18.1%)	71(23%)	0.43	0.501
Total	90	110	200	0.55	0.499

Chi square value	Gender wise
	15.082
P value	0.002*



Graph 7: Distribution of Dermatoglyphic Patterns in Hypertensive Patients and Type II Diabetes Mellitus Patients

Table 8

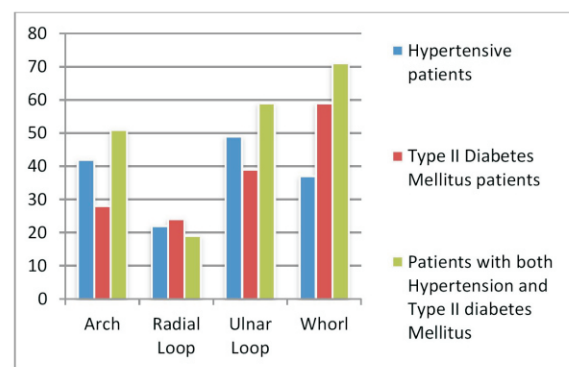
Dermatoglyphic patterns analysis was compared in group 1,2 and 3 patients. Ulnar loop type of pattern(36.6%) was predominantly seen in group 1 patients followed by whorl pattern (24.60%),arch pattern (24%) and radial loop pattern (14.6%).Chi square test value for group 1 was 7.408 and p value was 0.060 that is insignificant. In group 2 patients whorl type of pattern(39.3%) was predominantly seen followed by ulnar loop pattern (26%),arch pattern(18.6%) and radial loop pattern(16%).Chi square test value was 7.296 for group 2 patients and p value was insignificant that is 0.063.In group 3 patients whorl type of pattern(35.5%) was predominantly seen followed by ulnar loop pattern (29.5%),arch pattern(25.5%) and radial loop pattern(9.5%).Chi square test value was 3.815 for group 3 patients and p value was insignificant that is 0.282.

Comparison of Dermatoglyphic Patterns in Hypertensive patients, Type II Diabetes Mellitus Patients and Patients with both Hypertension and Type II Diabetes Mellitus

Table No 8

Ridge pattern	Hypertensive Patients	Type II Diabetes Mellitus Patients	Patients with both Hypertension and Type II Diabetes Mellitus.	Total
Arch pattern	42(24%)	28(18.6%)	51(25.5%)	121(24.2%)
Radial loop pattern	22(14.6%)	24(16%)	19(9.5%)	65(13%)
Ulnar loop pattern	49(36.6%)	39(26%)	59(29.5%)	147(29.4%)
Whorl pattern	37(24.6%)	59(39.3%)	71(35.5%)	167(33.4%)
Total	150	150	200	500

Chi-square value	Hypertensive patients	Type II Diabetes Mellitus patients	Patients with both Hypertension and Type II Diabetes Mellitus.
	7.408	7.296	3.815
P value	0.060*	0.063*	0.282



Graph 8 : Comparison of Dermatoglyphic Patterns in Hypertensive patients, Type II Diabetes Mellitus Patients and Patients with both Hypertension and Type II Diabetes Mellitus

**Discussion:**

All human being have a unique genetical makeup that causes him/her to have unique patterns or traits, among which cheilosopic and dermatoglyphic patterns play a significant role.

Hypertension (HTN) is a major reason behind cardiovascular disorders which affects almost 1.3 billion people world widely and causes 17.9 million deaths annually. 75% of deaths related to hypertension occur in low and middle-income countries, where the prevalence of the disease is higher and there is a lower level of knowledge and awareness when compared to high-income countries.

According to **WHO**, diabetes mellitus will be the 7<sup>th</sup> leading cause of death by 2030. The prevalence of diabetes mellitus (DM) is growing at a rapid rate and is on the verge of becoming epidemic.

### For Cheilosopic patterns:

The results from the study group as illustrated in table 1 indicated that among patients solely diagnosed with hypertension, the branched type of cheilosopic pattern predominated and was seen in around 36% of patients, followed by straight type of pattern (22.60%) and intersected type of pattern (21.3%). Reticular type of pattern was less frequent (16%). However no statistically significant difference regarding genders was observed in hypertensive patients (p value = 0.743). Result of our study with respect to cheilosopic patterns in hypertensive patients was in compliance with the research done by **Umana et al. (2014)** where branched type of cheilosopic pattern had higher frequency in hypertensive patients (62.2%) when compared to normal individuals (53.5%). Although statistically significant difference was seen with respect to genders in the study of **Umana et al. (2014)** where branched type of patterns was less frequent in males when compared with females. **Magda et al. (2010)** also observed a greater prevalence of branched patterns in males compared to females.[6]

In our study patients who were solely diagnosed with type II DM (Table 2), reticular type of pattern (34.6%) predominated in both the genders followed by branched (26.6%) and intersected type of pattern (18.6%) respectively. Straight type of pattern (18%) was less frequent in both genders. Hence no statistically significant difference was seen with respect to genders (p value = 0.561). Similar findings were found in the study conducted by **Ramanathan et al. (2020)** where patients with diabetes mellitus had a considerably predominance of reticular type of pattern when compared with normal individuals.[7]

**Manjusha et al. (2017)** also reported that reticular type of cheilosopic pattern was more prevalent in DM patients.[8]

In our study, patients with both HTN and type II DM (Table 3) reticular type of pattern was seen more predominately that is 35.5% in males followed by branched pattern (30%) where as in females intersected type of pattern predominated that was 30% followed by branched pattern (28.1%). Here statistically significant difference was seen with respect to genders (p value = 0.024<sup>^</sup>). The comparison of the HTN patients, type II DM patients and patients with both HTN and type II DM was calculated with respect to cheilosopic patterns as illustrated in table 4 and it was concluded that branched and reticular type of pattern were most common. The result was in

compliance with the research conducted by **Jeddy et al. (2019)** who evaluated that the patients with type II DM tended to have branched and reticular type of lip print patterns. A study conducted by **Umana et al. (2013)** on **Nigerian** population concluded that reticular type of pattern had more incidence of type II DM. Although our North Indian population is genetically distinct from Nigerian population still the prevalence of reticular type of pattern was equally seen in both populations suffering from type II diabetes mellitus.[9]

Cheilosopic patterns have been found at variable frequency across different populations across the world. **Tsuchikashi (1974)** found type II as most prevalent in **Japanese population**. In **India**, **Vahanwalla and Parekh (2001)** found the prevalence of branched type of lip print pattern. Additionally, according to **Patel et al. (2010)** Type II (branched – 42%) was found to be the most prevalent pattern in both genders in normal individuals and reticular pattern was least common in both genders. However we concluded the prevalence of both branched and reticular type of patterns as most common in patients with HTN and type II DM (Table 4). These findings encourage the connection between the cheilosopic patterns and the prevalence of the disease.

### For Dermatoglyphics patterns :

The results of study group as illustrated in table 5 indicated that the patients diagnosed with hypertension showed the predominance of ulnar loop pattern (36.6%) in both the genders followed by whorl pattern (24.6%) where as in males, arch type of pattern (31.6%) was second most common where as in females whorl type of pattern (32.2%) was seen predominately after ulnar loop pattern (35.5%). Therefore, a significant statistical difference was seen between genders among patients diagnosed with HTN (p value=0.008\*). The findings were in concurrence with the outcome of the study undertaken by **Lahiri et al. (2013)** where the loop patterns were predominantly seen over other patterns. **Umana et al. (2014)** also concluded the predominance of loop and whorl patterns in HTN patients. [10]

In contrast **Tafazoli et al. (2013)** found the predominance of arch pattern in HTN group when compared with normal individuals. [11]

**Edward et al. (2007)** concluded that the development of proximities and cardiovascular system transpires

simultaneously and hence a relationship can be defined between hypertension with dermatoglyphic patterns.[12]

However in contrast **Stevenson et al. (2001) in their study of adolescents with hypertension** found no relation between dermatoglyphic patterns and hypertension.[13]

Patients with solely type II DM (Table 6) showed the predominance of whorl type of pattern (39.3%) followed by ulnar loop type of pattern (26%) and patients with both HTN and type II DM (Table 7) showed the predominance of ulnar loop type of pattern (47%) followed by whorl type of pattern (23%). Statistical significant difference ( $p$  value = 0.016\*) was observed with respect to gender in patients with type II DM (Table 6). Patients with both HTN and type II DM (Table 7) showed the predominance of ulnar loop type of pattern (47%) followed by whorl type of pattern (23%). Statistical significant difference ( $p$  value = 0.002\*) was observed with respect to genders in patients with both HTN and type II DM (Table 7) In males, ulnar loop type of pattern (35.7% in type II DM and 43.3% in both HTN and type II DM) was predominant in both study groups where as in females whorl type of pattern that is 50% in patients of type II DM predominated and in patients of both HTN and type II DM ulnar loop type of pattern predominated. The results were in compliance with the study of **Kakkeri et al. (2018)** where in 67% of diabetic patients showed the predominance of whorl pattern followed by loop pattern.[14]

However **Srivastva and Rajasekar (2014)** concluded the predominance of whorl pattern in diabetes mellitus patients in both the genders.[15]

Therefore, a substantial association between the dermatoglyphic patterns and the incidence of the disease was established through the results of our study. In compliance to the results of this study similar significant correlations were established by **Chakravarthy et al. (2018)**. [16]

**Bala et al. (2015)** also found the meaningful relationship between dermatoglyphic patterns and diabetes mellitus patients with hypertension.[17]

### Conclusion:

The outcome of this study demonstrated the significant relation between branched and reticular type of cheiloscopy patterns and the patients of hypertension and type II diabetes mellitus.

The whorl pattern in dermatoglyphic patterns may serve as a reliable indicator in adults with type II diabetes mellitus. Dermatoglyphic patterns as well as cheiloscopy patterns, remain unchanged throughout a person's life, representing genetically determined traits. These patterns exhibit permanence and stability, maintaining their original form and characteristics. Notably, there appears to be a significant relationship between specific finger print and lip print patterns in genetically influenced conditions such as HTN and type II DM.

### References:

1. Khatimah H, Rosida L. Whorl pattern and total ridge count on patient with essential hypertension at Ullin Hospital Banjarmasin. *Mutiara Medika*. 2013;13:84–8. [[Google Scholar](#)]
2. Mhaske SP, Jagtap K, Deshpande R. Cheiloscopy: Tool for forensic identification. *IJDPM*. 2013;1:6–8. [[Google Scholar](#)]
3. Deshpande A, Gokak KV, Kashyap B, Bagewadi A. Association and correlation of dermatoglyphics and cheiloscopy in head and neck cancer-Unsuarling conundrum. *Ind J Appl Res*. 2019;9:56–9. [[Google Scholar](#)]
4. Ojha P, Gupta G. Dermatoglyphic study: A comparison in hands of type II diabetes mellitus patients and normal persons of Udaipur region. *J Evol Med Dent Sci*. 2014;3:11358–68. [[Google Scholar](#)]
5. Shende PD, Jangam DK. Study of lip print patterns among patients visiting dental college: A descriptive study. *Int J Recent Sci Res*. 2019;10:36322–34. [[Google Scholar](#)]
6. Umana UE, Netete BV, Timbuak JA, Ibegu JA, Musa AO, Hammam WO. Dermatoglyphics and cheiloscopy patterns in hypertensive patients: A study in Ahmadu Bello Univ Teaching Hospital, Zaria, Nigeria and Environs. *Int J Sci Res Publ*. 2014;4:1–5. [[Google Scholar](#)]
7. Ramanathan V, Kumaran JV, Srinivasan SV, Daniel MJ. Analysis of lip prints as a predictive tool in screening Type 2 diabetes mellitus – A cross-sectional study. *SRM J Res Dent Sci*. 2020;11:138–41. [[Google Scholar](#)]
8. Manjusha P, Sudha S, Shameena PM, Chandni R, Varma S, Pandiar D. Analysis of lip print and fingerprint patterns in patients with type II diabetes mellitus. *J Oral Maxillofac Pathol*. 2017;21:309–15. doi: 10.4103/jomfp.JOMFP\_17\_16. [[DOI](#)] [[PMC free article](#)] [[PubMed](#)] [[Google Scholar](#)]

9. Jeddy N, Radhika T, Sai Lakshmi L J, Khodabux RJ, Srilekha R, Sruthi G. Cheiloscopy and dermatoglyphics as screening tools for type 2 diabetes mellitus. *J Forensic Dent Sci.* 2019;11:163–6. doi: 10.4103/jfo.jfds\_87\_19. [[DOI](#)] [[PMC free article](#)] [[PubMed](#)] [[Google Scholar](#)]
10. Lahiri A, Bandhopadhyay S, Adhya S, Ghosh S, Goswami S, Bhattacharya P. A study on relationship between dermatoglyphics and hypertensives. *IOSR J Dent Med Sci.* 2013;7:62–5. [[Google Scholar](#)]
11. Tafazoli M., Dezfooli S.R., Shahri N.M. The study of dermatoglyphic patterns and distribution of the minutiae in inherited essential hypertension disease. *Curr Res J Biol Sci.* 2013;5:252–261. [[Google Scholar](#)]
12. Edward DC. Fingerprint and palmar dermatoglyphics. Available from: <https://007.www.pdc.co.ildiakses>. [1 April 2]
13. Stevenson CJ, West CR, Pharaoh PO. Dermatoglyphic patterns, very low birth weight and blood pressure in adolescents. *Arch Dis Child Fetal Neonatal Ed.* 2001;84:F18–21. doi: 10.1136/fn.84.1.F18. [[DOI](#)] [[PMC free article](#)] [[PubMed](#)] [[Google Scholar](#)]
14. Kakkeri SR, Attar H, Khan J. Correlation between fingerprint patterns in type-II diabetes mellitus. *Al Ameen J Med Sci.* 2018;11:161–5. [[Google Scholar](#)]
15. Srivastava S, Rajasekhar SS. Comparison of digital and palmar dermatoglyphic patterns in diabetic and non-diabetic individuals. *IOSR J Dent Med Sci.* 2014;13:93–5. [[Google Scholar](#)]
16. Chakravarthy GP, Shirali A, Chowta KN, Ramapuram JT, Madi D, Chouhan RRS. A “handy” tool for hypertension prediction: Dermatoglyphics. *Ind Heart J.* 2018;70:S116–7. doi: 10.1016/j.ihj.2018.07.007. [[DOI](#)] [[PMC free article](#)] [[PubMed](#)] [[Google Scholar](#)]
17. Bala A, Desmal A, Sarmah PC, Khandalwal B, Tamang BK. Palmar dermatoglyphic patterns in diabetes mellitus and diabetes with hypertension patients in Gangtok region. *Int J Adv Res.* 2015;3:1117–25. [[Google Scholar](#)]